



PRESENTING CLINICAL SIGNS

DATE History: Murmur. Tracheal collapse. Coughing recently. Started on hydrocodone. Pre-anesthetic evaluation (dental).

4/15/22

ECHOCARDIOGRAPHIC FINDINGS

2D, M-mode, and Doppler study.

PERFORMED BY:

Dr. Meredith Swart

There is mild left atrial dilation. The mitral valve leaflets are thickened and exhibit systolic prolapse. A mild to moderate jet of eccentric mitral regurgitation is present. There is mild left ventricular dilation. Left ventricular systolic function is hyperdynamic. The aorta and aortic valve are normal. Right atrial and right ventricular dimensions are normal. The tricuspid valve is normal. The pulmonary artery and pulmonic valve are normal. No pericardial effusion or cardiac masses are seen.

INTERPRETED BY

Keith Blass, DVM,
MS, DACVIM
(Cardiology)

LA - 23.7 mm
LVIDd - 24.1 mm
LVIDs - 13.0 mm
FS - 46%
LVOT - 1.20 m/s
RVOT - 0.83 m/s

PATIENT

Bella Magriz

ASSESSMENT/RECOMMENDATIONS

Degenerative mitral valve disease

SPECIES

Canine

This examination demonstrates mild to moderate regurgitation of blood across Bella's mitral valve resulting from degenerative valve disease. Secondary to her regurgitation, Bella has mild dilation of both her left atrium and left ventricle, though her left ventricular systolic function is well-preserved. As only mild left heart chamber dilation is present, it's unlikely that there is a cardiac contribution to Bella's cough, and her current risk for the development of left-sided congestive heart failure does not appear to be significantly elevated.

BREED

Chihuahua

Bella's cardiovascular risk for general anesthesia is mildly to moderately increased based on this exam, therefore, some precautions should be taken in order to minimize this risk. I recommend avoiding the use of alpha-2 agonists, ketamine, and telazol in the anesthetic protocol, as well as reducing the IV fluid rate by at least 25%. If possible, monitoring of heart rhythm, blood pressure, and pulse oximetry are recommended during the procedure.

SEX

FS

AGE

11 y

I recommend starting Bella on pimobendan (1.25 mg BID), as this medication should help to slow the progression of her mitral valve disease, as well as decrease her risk for general anesthesia.

A recheck echocardiogram is recommended in 9 months. Thoracic radiographs are recommended if Bella's cough worsens, or she experiences an increased respiratory rate/effort.

WEIGHT

8.0 lb

HOSPITAL NAME

Swart Veterinary
Imaging

REFERRING VET

Dr. Swart



DATE

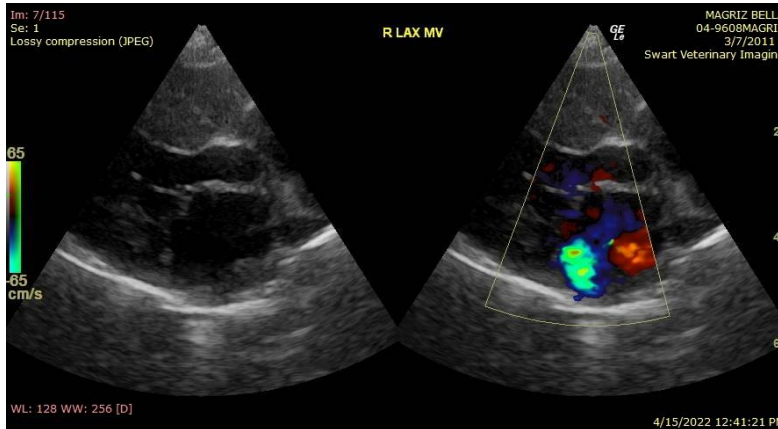
4/15/22

PERFORMED BY:

Dr. Meredith Swart

INTERPRETED BY

Keith Blass, DVM,
MS, DACVIM
(Cardiology)



The information and recommendations provided are based on the images presented by the referring veterinarian. No evaluation can be communicated regarding pathology that was not visible in the image/video clips provided.

PATIENT

Bella Magriz

Thank you for this referral. If the clinical or image interpretation does not parallel your findings or if I can be of any further assistance please contact me.

SPECIES

Keith Blass, DVM, MS, DACVIM (Cardiology)

Canine

KeithBlass@gmail.com

631-804-5754

BREED

Chihuahua

SEX

FS

AGE

11 y

WEIGHT

8.0 lb

HOSPITAL NAME

Swart Veterinary
Imaging

REFERRING VET

Dr. Swart